The use of Doppler in twin pregnancies

L Lewi University Hospitals Leuven Belgium

Dichorionic twin pregnancy

Monochorionic twin pregnancy

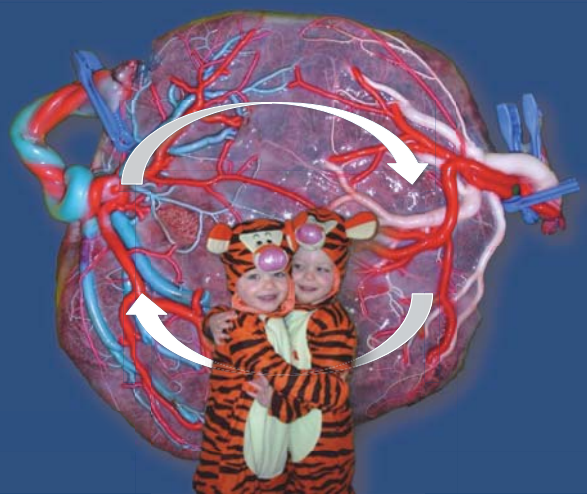

Monochorionic twin pregnancy

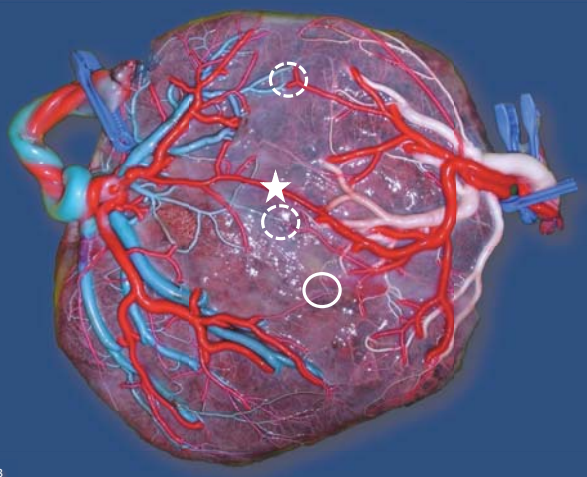

Monochorionic twin pregnancy

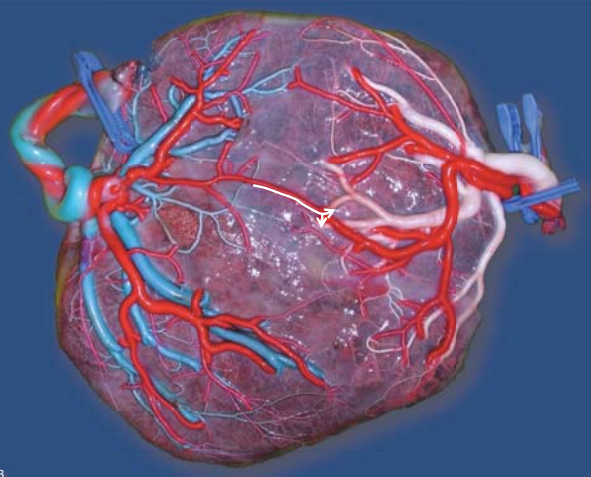

Lewi L, AJOG 2013

4

Monochorionic twin pregnancy

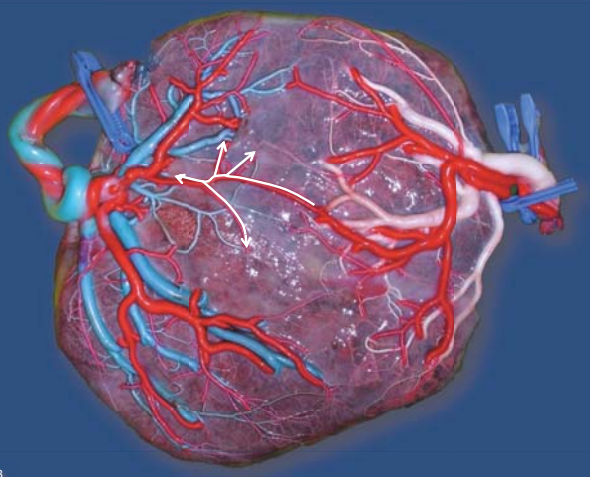

Lewi L, AJOG 2013

5

Determination of cord insertion sites

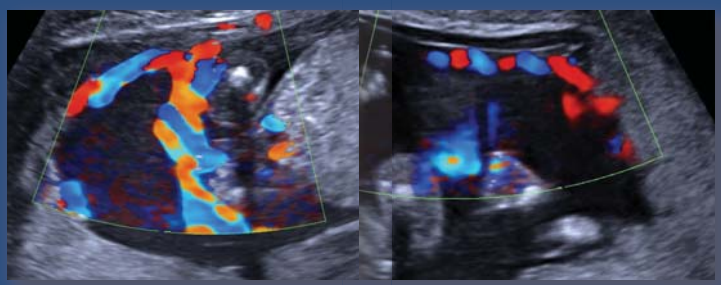

Sepulveda W, UOG 2003, Sepulveda W, J Ultrasound Med 2006

2

Determination of cord insertion sites

In 50% of monochorionic twin pregnancies have discordant cord insertions

Couck I, UOG 2018

1

Determination of cord insertion sites

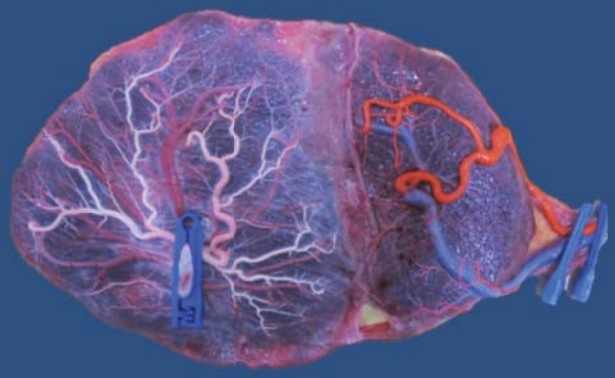

20% of monochorionic twin have a velamentous cord insertion in 1 or both twins

Couck I, UOG 2018

Determination of cord insertion sites

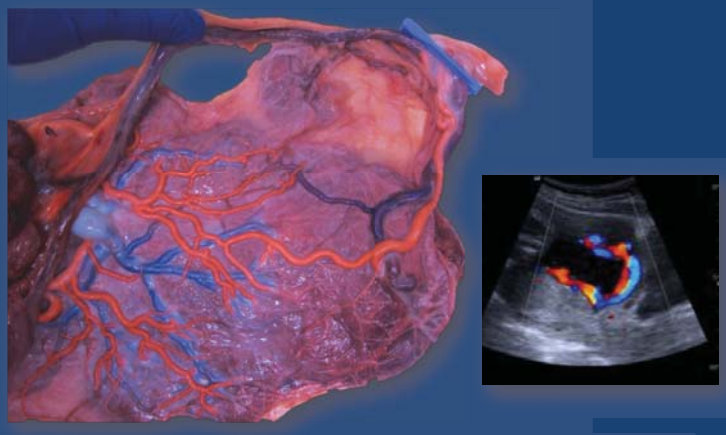

Jauniaux E, AJOG 2017

Evaluation of discordant growth in monochorionic twin pregnancies

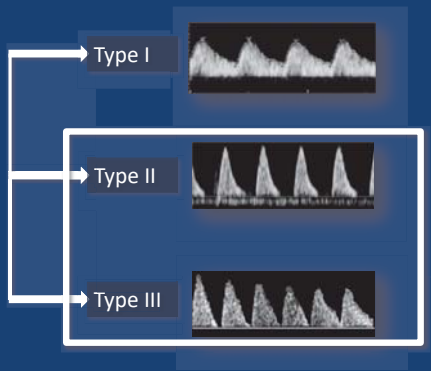

Gratacos E, UOG 2004; Gratacos E, UOG 2007

Evaluation of discordant growth in monochorionic twin pregnancies

Type II

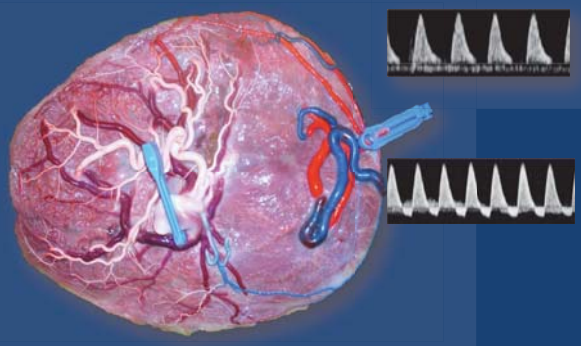

60% survival - 90% progressive deterioration

Gratacos E, UOG 2004; Gratacos E, UOG 2007; Lewi L, AJOG 2008; Ishii K, UOG 2011

Evaluation of discordant growth in monochorionic twin pregnancies

Type III

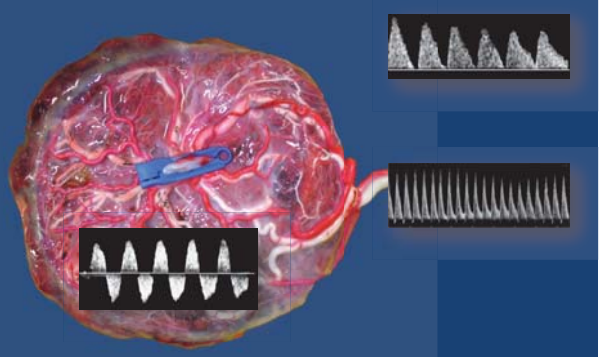

85 % survival - in 15% unpredictable demise of the smaller twin

Gratacos E, UOG 2004; Gratacos E, UOG 2007; Lewi L, AJOG 2008; Ishii K, UOG 2011

Staging for twin-twin transfusion syndrome

- Stage I: bladder in donor-normal Dopplers

- Stage II: no bladder in donor-normal Dopplers

- Stage III: AREDF in A.Umb and/or negative A-wave duct

- Stage IV: Hydrops

- Stage V: In utero death of 1 or both twins

Quintero R, J Perinatol 1999

Diagnosis of twin anemia polycythemia sequence

Δ MCA-PSV > 0.5 MoM

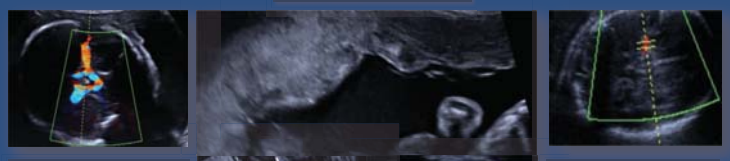

MCA-PSV > 1.5 MoM

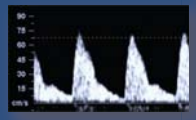

MCA-PSV < 1 MoM

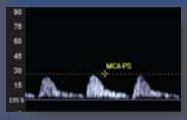

Lewi L, AJOG 2006-2008 ; Lopriore E, Placenta 2007; Lopriore E, Fetal Diagn Ther 2010; Tollenaere LSA, UOG 2018; www.trialregister.nl/trialreg/admin/rctview.asp?TC=7057

Diagnosis of twin anemia polycythemia sequence

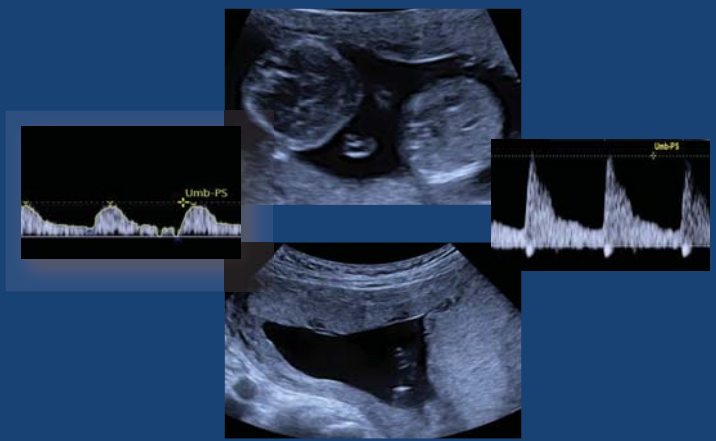

15 weeks, 20% EFW discordance, MCA PSV >1.5 MoM and = 1 MoM

Diagnosis of twin anemia polycythemia sequence

Discordance disappeared by 23 weeks to become progresively more discordant from 27 weeks

Diagnosis of twin anemia polycythemia sequence

Smaller twin 1250g
Hb 13 g/dL

Larger twin 1650g
Hb 20.8 g/dL

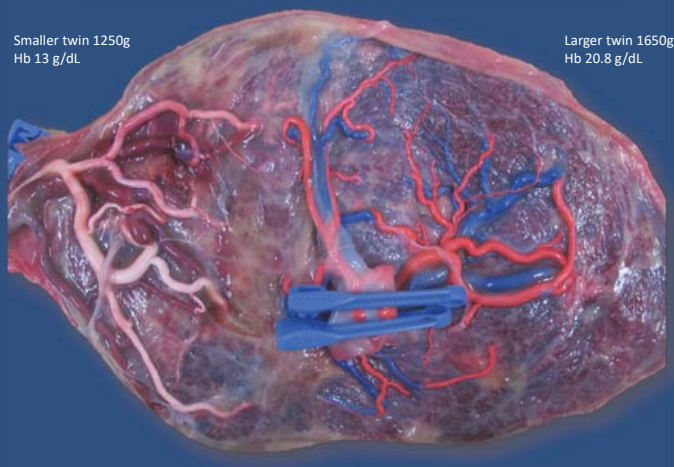

PPROM at 31 weeks, no visible anastomoses on the chorionic surface

Evaluation of surviving twin after single demise

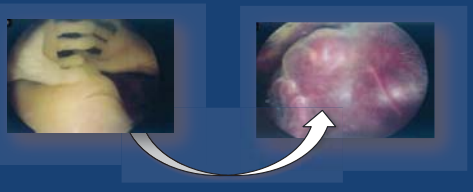

40% co-twin demise & 25% risk of brain damage

Quintero R, UOG 2003; Lewi L, AJOG 2008; Hillman SC, Obstet Gynecol 2011

Diagnosis of MOMA twins in the first trimester

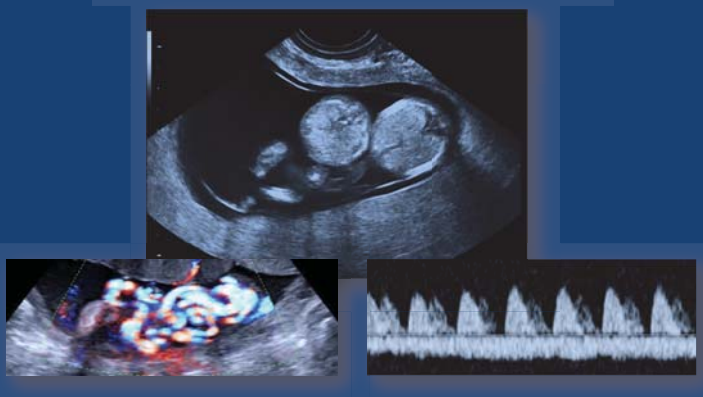

Overton TG, Ultrasound Obstet Gynecol 1999; Arabin B, Ultrasound Obstet Gynecol 1999; Sebire NJ, Ultrasound Obstet Gynecol 2000

Follow-up of MOMA twins

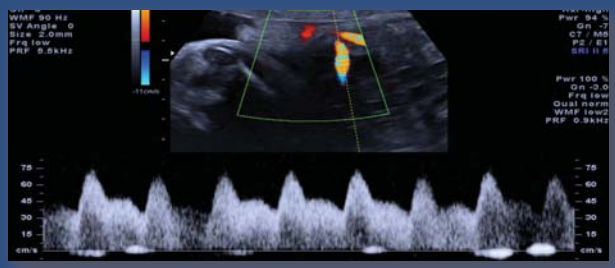

Aurioles-Garibay A, Fetal Diagn Ther 2014

Diagnosis of TRAP or acardiac twinning

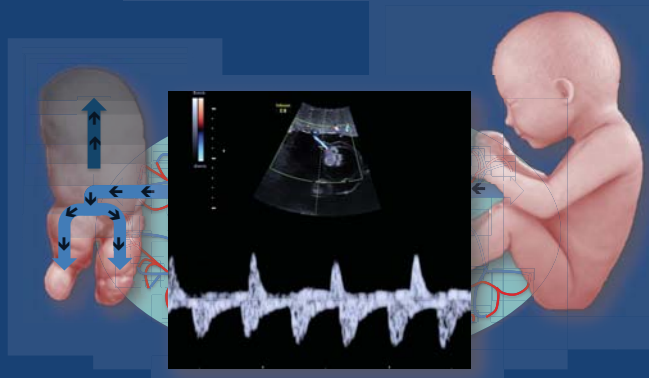

Van Allen MI, Semin Perinatol 1983

Take home message!

- Doppler ultrasound is important for the surveillance of twin pregnancies

Thank you!